

# EVALUATION OF THE EFFECT OF *PTYCHOPETALUM OLACOIDES* (MUIRA PUAMA) EXTRACT ON ALUMINIUM CHLORIDE-INDUCED NEUROTOXICITY IN RATS.

Ajao Joshua Aduragbemi<sup>1</sup>, Akinsehinwa Akinsanmi Festus<sup>2</sup> Onaolapo Olakunle James<sup>1,3</sup>,  
Onaolapo Adejoke Yetunde<sup>2,4</sup>.

1. Department of Pharmacology and Therapeutics, Ladoke Akintola University of Technology, Ogbomoso, Oyo State, Nigeria
2. Department of Anatomy, Ladoke Akintola University of Technology, Ogbomoso, Oyo State, Nigeria.
3. Behavioural Neuroscience and Neuropharmacology Unit, Department of Pharmacology and Therapeutics, Ladoke Akintola University of Technology, Ogbomoso, Oyo State, Nigeria
4. Behavioural Neuroscience and Neurobiology Unit, Department of Anatomy, Ladoke Akintola University of Technology, Ogbomoso, Oyo State, Nigeria

## Corresponding Author

Dr Mrs AY Onaolapo

Behavioural Neuroscience and Neurobiology Unit,

Department of Anatomy,

Ladoke Akintola University of Technology,

Ogbomoso, Oyo State, Nigeria

Email : [ayonaolapo@lautech.edu.ng](mailto:ayonaolapo@lautech.edu.ng) Phone 2349020391763

## ABSTRACT

Muira puama is a plant renowned for its potent antioxidant and neuroprotective properties. The effects of ethanol extract of Muira puama on aluminium chloride-induced changes in rat behaviour and cerebral cortex histomorphology was examined in this study. Fifty male rats weighing 120-150 g each were divided into six groups: control (normal saline), Muira puama extract groups (25 mg/kg and 50 mg/kg), AlCl<sub>3</sub> group (100 mg/kg), and AlCl<sub>3</sub> combined with Muira puama extract groups (25 mg/kg and 50 mg/kg respectively). All treatments were administered orally for 21 days. Behaviours were assessed after the final dose of treatment. The result showed that the administration of AlCl<sub>3</sub> was associated with decreased weight gain, behavioural alterations, and spatial working memory deficits. However, co-treatment with Muira puama was associated with increased food intake, reversal of weight loss, enhanced locomotion/self-grooming, and reduction of anxiety. Additionally, spatial working memory scores were significantly improved with Muira puama. Biochemical analysis showed reduced levels of malondialdehyde and tumour necrosis factor- $\alpha$ , and increased levels of interleukin 10 and total antioxidant capacity. Histological examination revealed neuronal preservation with Muira puama, suggesting protective effects on the cerebral cortex. These findings suggest that Muira puama extract has the ability to mitigate aluminium chloride-induced changes in rats. However, more studies would be needed to determine its suitability for use in humans.

**KEYWORDS:** Aluminium Chloride; Muira puama; Neurotoxicity; Neuroinflammation; Neuroprotection

## 1. Introduction

Aluminium chloride (AlCl<sub>3</sub>) is a molecule with extensive industrial and medical applications, and it is primarily derived from aluminium-containing metal ores [1]. Additionally, soluble aluminium compounds, including AlCl<sub>3</sub>, are frequently used in water purification and food packaging, exposing humans to potential health risks [2]. Human exposure to aluminum chloride (AlCl<sub>3</sub>) can occur through various pathways, including inhalation of dust or fumes in occupational and industrial environments, dermal absorption from consumer products such as antiperspirants, and, to a lesser extent, through ingestion. [3]. The neurotoxicity of AlCl<sub>3</sub> exposure is particularly alarming, since both clinical and preclinical investigations associate it with cognitive impairment and various central nervous system (CNS) disruptions [4]. Once it enters the body Aluminium chloride cross the blood-brain barrier (BBB) and aggregate in multiple brain regions, such as the cerebral cortex, cerebellar cortex, amygdala and hippocampus [5]. These regions of the brain govern higher cognitive functions, including memory, attention, and decision-making, and is notably affected

by exposure to aluminium chloride. The neurotoxic potential of Aluminium chloride is increasingly recognised, with accumulating evidence linking prolonged exposure to neurological disorders, including Alzheimer's disease [6]. The accumulation of aluminium in brain tissues is believed to intensify oxidative stress, disrupt cellular metabolism, and impair neuronal function [7]. Considering the neurodegenerative potential of  $\text{AlCl}_3$  and its pervasive presence in the environment and everyday items, there is an urgent need to explore therapies that can mitigate the harmful effects. Numerous pharmaceutical drugs have been used to address neurodegeneration, but these often come with limitations, including side-effects and inability to reverse the structural and biochemical alterations caused by  $\text{AlCl}_3$ . Despite these challenges, the use of plant extracts as interventions remains relatively underexplored. Muira puama, a plant renowned for its potent antioxidant and neuroprotective properties, offer a promising alternative therapeutic approach for combating aluminium chloride induced neurotoxicity. The current study examined the potential benefits of Muira puama extract as a natural therapeutic intervention to counteract aluminium chloride induced cognitive and structural brain impairments, and also to provide insight into managing  $\text{AlCl}_3$  related neurodegeneration.

The objectives of this study were to assess the effect of Muira puama on body weight, food intake, open field locomotion and exploratory behaviours, spatial working memory in the Y maze, and anxiety related behaviours in the elevated plus maze in rat exposed to Aluminium chloride. Additionally, the study aimed to investigate the impact of *Muira puama* on lipid peroxidation, total antioxidant capacity, and inflammatory cytokines, specifically  $\text{TNF-}\alpha$  and IL-10. Furthermore, the study sought to examine changes in the histoarchitecture of the cerebral cortex using Hematoxylin and Eosin staining as well as Cresyl Fast Violet staining in response to aluminium chloride-induced neurotoxicity.

## **2. Materials and Methodology**

### **2.1 Chemicals and Drugs**

Muira puama root extract (Cheryls Herbs), Aluminium chloride (Sigma-Aldrich Corporation, USA), Interleukin-10 assay kit (Biovision Inc., Milpitas, CA, USA). Tumour necrosis factor alpha ( $\text{TNF } \alpha$ ) assay kit (Biovision Inc., Milpitas, CA, USA). Total antioxidant capacity (TAC) assay kit (Biovision Inc., Milpitas, CA, USA).

### **2.2 Animals**

Healthy male Wistar rats used in this study were obtained from Empire Breeders, Osogbo, Osun State Nigeria. Rats were housed in wooden cages measuring 20 x 10 x 12 inches in temperature-controlled ( $22.5^\circ\text{C} \pm 2.5^\circ\text{C}$ ) quarters with lights on at 7.00 am. Rats were allowed free access to food and water. All procedures were conducted in accordance with the approved protocols of the Faculty of Basic Medical Sciences, Ladoke Akintola University of Technology, abiding by the regulations for animal care and use outlined in European Council Directive (EU2010/63) on scientific procedures involving living animals.

### **2.3 Experimental Methodology**

A total of fifty male rats weighing 120-150g each were randomly assigned into six groups ( $n=10$  each). Group A (control group) received 10 ml/kg of Normal saline, group B (Muira puama extract control group) received 25 mg/kg of Muira puama extract, group C (Muira puama extract control group) received 50 mg/kg of Muira puama extract, group D (Aluminium chloride ( $\text{AlCl}_3$ ) control) received 100 mg/kg of  $\text{AlCl}_3$ , group E received 100 mg/kg of  $\text{AlCl}_3$  and 25 mg/kg of Muira puama extract, group F received 100 mg/kg of  $\text{AlCl}_3$  and 50 mg/kg of Muira puama extract. All agents were administered orally by gavage with the aid of a canula for a period of 21 days; with dosages determined based on evidences from previous research [8]. After treatment, animals underwent behavioural tests (elevated plus maze, open field, and Y-maze). Twenty-four hours post-testing, rats were euthanised by cervical dislocation, and blood was drawn for analyses of interleukins (interleukin (IL)-10 and Tumour necrosis factor ( $\text{TNF}\alpha$ ), malondialdehyde (MDA), and total antioxidant capacity (TAC). Brains were excised, fixed in 10% formol-calcium, and cerebral cortex sections were processed, embedded in paraffin, and stained for histological evaluation.

### **2.4 Behavioural Testing**

#### **2.4.1 Open field Behaviours**

Open-field behaviours in rats encompass stimulation, suppression and observational exploration, alongside anxiety-related actions as described by [9]. This paradigm also highlights stereotypic behaviours, such as grooming, which are commonly recognised as fundamental indicators of a rodent's exploratory capacity. In this study, a 10-minute observation period was conducted in the open-field apparatus, during which behaviours such as grooming, rearing, and horizontal movement were recorded and documented. The open field apparatus is a rectangular arena made of white-painted wood, measuring 36 x 36 x 26 cm. The floor is made of hard wood and divided by permanent red markings into 16 equal-sized squares. The rats were placed in the centre of the field. Generally, spontaneous motor activity was monitored in the open-field as previously described by [10]. The total horizontal locomotion (number of floor units entered with all paws), rearing frequency (number of times the animal stood on its hind legs either with its fore-arms against the walls of the observation cage or free in the air) and frequency of grooming (number of body cleaning with paws, picking of the body and pubis with the mouth, and face-washing actions, indicative of a stereotypic behaviour) within the 10-minute period was recorded.

#### **2.4.2 Anxiety Behaviour**

The elevated plus-maze, as described by [11], is a cross-shaped apparatus with four arms arranged at right angles. Two open arms, each 25 x 5 x 5 cm, are opposite two closed arms of the same length and width but with a 16 cm high wall for enclosure. A central platform, measuring 5 x 5 x 0.5 cm, connects the arms. Following the administration of Aluminium Chloride, Muira puama or Normal saline, rats were placed on the central platform facing a closed arm, and their behaviour was observed for 5 minutes, following protocols previously described by [12] [13]. An entry into an arm was only counted if the rat fully entered with all four limbs. After each trial, the maze was cleaned with 5% ethanol. The elevated plus-maze assesses rodents' preference for dark, enclosed spaces (approach) versus their instinctive fear of open, elevated areas (avoidance). The percentage of time spent in the arms was calculated as: (time in open or closed arms / total time) x 100. The number of entries into each arm type was calculated as: (number of entries into open or closed arms / total entries).

### **2.5 Biochemical Test**

#### **2.5.1 Lipid Peroxidation**

Lipid peroxidation levels were evaluated by measuring malondialdehyde content assessed as levels of thiobarbituric acid reactive substance in the biological samples. Combination of free malondialdehyde and thiobarbituric acid reactive substance forms coloured complex which can be measured spectrophotometrically. Concentration of which is expressed as  $\mu\text{mol}$  following the instructions of the kit manufacturer.

#### **2.5.2. Antioxidant Status**

Total antioxidant capacity was assayed using the Trolox Equivalent Antioxidant Capacity Assay method that assesses the ability of antioxidants within a given sample to react with oxidised products as previously described by [14].

#### **2.5.3 Interleukin (IL) -10 and Tumour Necrosis Factor- $\alpha$**

Interleukin (IL)-10 and Tumour necrosis factor - $\alpha$  levels were measured using the enzyme-linked immunosorbent assay techniques with commercially available kits (Biovision Inc., Milpitas, CA, USA).

### **2.6 Tissue Histology**

Rat brains were dissected, sectioned and fixed in neutral-buffered formol calcium. The cerebral cortex was then processed for paraffin-embedding, cut at 5  $\mu\text{m}$  and stained with haematoxylin and eosin and cresyl fast violet for general histological study.

### **2.7 Photomicrography**

Histological slides of the cerebral cortex were examined under an Olympus binocular light microscope. Images were captured using a Canon PowerShot 2500 Digital camera.

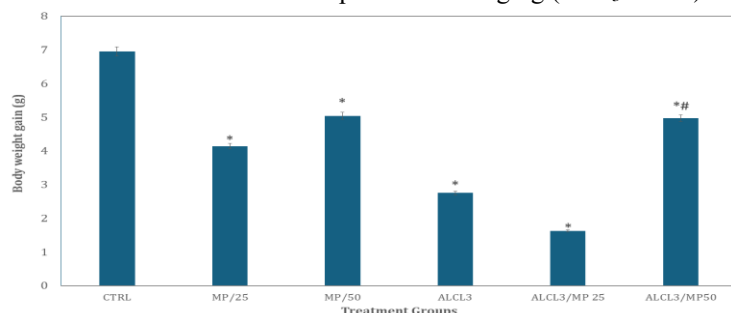
### **2.8 Statistical Analysis**

Data was analysed using Chris Rorden's ANOVA for Windows (version 0.98). Analysis of data was by One-way analysis of variance (ANOVA) and a post-hoc test (Tukey HSD) used. All results were expressed as mean  $\pm$  S.E.M. and  $p < 0.05$  was taken as the accepted level of significant difference from control.

### 3. Results

#### 3.1 Effect of Muira puama on body weight

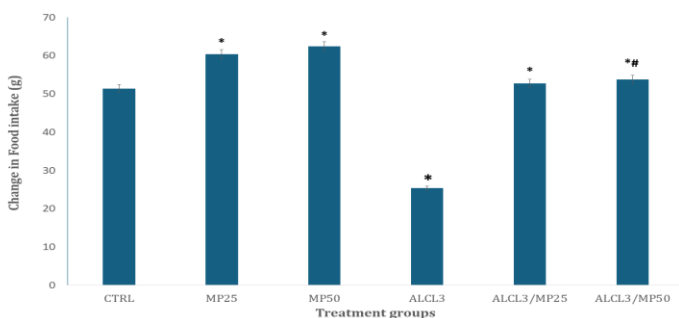
Figure 1 shows the effect of Muira puama extract on the relative alterations in body weight in rats. There was a significant ( $p < 0.001$ ) reduction in body weight gain with Muira puama (MP) at 25 and 50 mg/kg,  $AlCl_3$  and with  $AlCl_3$  and Muira puama ( $AlCl_3$ MP) at 25 and 50 mg/kg respectively compared to control. In comparison to  $AlCl_3$ , there was a significant decrease in body weight with  $AlCl_3$  and Muira puama at 25 mg/kg ( $AlCl_3$ MP25) while an increase was observed with  $AlCl_3$  and Muira puama at 50 mg/kg ( $AlCl_3$ /MP50).



**Figure 1** Effect of Muira puama extract on relative change in body weight. Each bar represents Mean  $\pm$  S.E.M, \* $p < 0.05$  significant difference from control. \*\* $p < 0.05$  significance difference from  $AlCl_3$ . Number of rats per treatment group = 10.  $AlCl_3$ : Aluminium chloride

#### 3.2. Effect of Muira puama on food intake

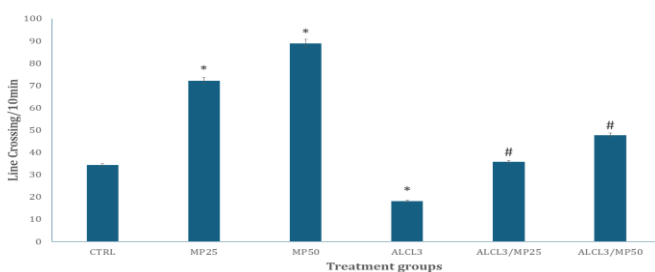
Figure 2 shows the effect of Muira puama extract on relative feed intake. There was a significant [ $p < 0.001$ ] increase in feed intake with MP25, MP50,  $AlCl_3$ /MP25,  $AlCl_3$ /MP50 and a significant decrease with  $AlCl_3$  compared to control. In comparison to  $AlCl_3$ , feed consumption increased with  $AlCl_3$ /MP25 and  $AlCl_3$ /MP50 respectively.



**Figure 2:** Effect of Muira puama extract on relative change in feed intake. Each bar represents Mean  $\pm$  S.E.M, \* $p < 0.05$  significant difference from control. \*\* $p < 0.05$  significance difference from  $AlCl_3$ . Number of rats per treatment group = 10.  $AlCl_3$ : Aluminium chloride.

#### 3.3 Effect of Muira puama on horizontal locomotion

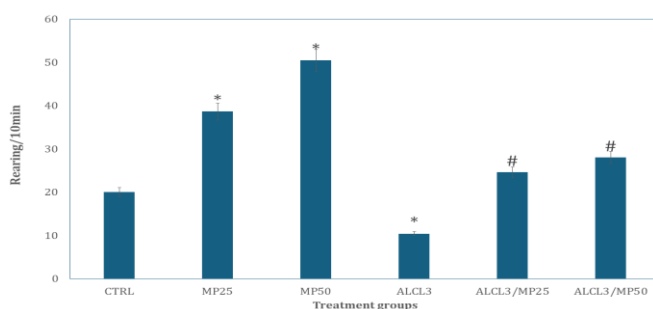
Figure 3 shows the effect of Muira puama extract on horizontal locomotor activity measured as number of line-crossings during a 10-minute period. There was a significant [ $p < 0.001$ ] increase in locomotor activity with MP25, MP50,  $AlCl_3$ /MP25,  $AlCl_3$ /MP50 and a significant decrease with  $AlCl_3$  compared to control. In comparison to  $AlCl_3$ , locomotor activity increased with  $AlCl_3$ /MP25 and  $AlCl_3$ /MP50 respectively.



**Figure 3:** Effect of Muira puama extract on Horizontal locomotion (line crossing) i Each bar represents Mean  $\pm$  S.E.M, \* $p < 0.05$  significant difference from control. # $p < 0.05$  significance difference from  $AlCl_3$ . Number of rats per treatment group = 10.  $AlCl_3$ : Aluminium chloride.

### 3.4 Effect of Muira puama on rearing activity

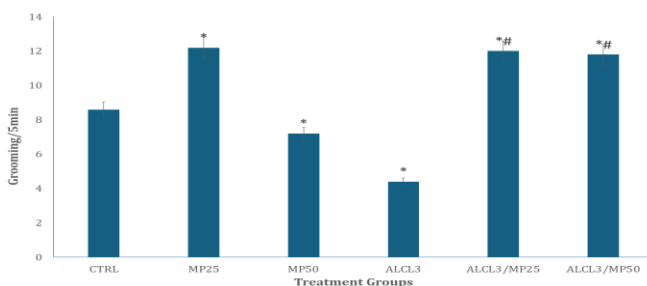
Figure 4 shows the effect of Muira puama on rearing behaviour. There was a significant [ $p < 0.001$ ] increase in rearing activity with MP25 and 50 and a significant decrease with  $AlCl_3$  compared to control. In comparison to  $AlCl_3$ , rearing activity increased with  $AlCl_3/MP25$  and  $AlCl_3/MP50$  respectively.



**Figure 4:** Effect of Muira puama extract on vertical locomotor activity (rearing). Each bar represents Mean  $\pm$  S.E.M, \* $p < 0.05$  significant difference from control. # $p < 0.05$  significance difference from  $AlCl_3$ . Number of rats per treatment group = 10.  $AlCl_3$ : Aluminium chloride.

### 3.5 Effect of Muira puama on self-grooming behaviour

Figure 5 shows the effect of Muira puama extract on self-grooming behaviour. There was a significant ( $p < 0.001$ ) increase in self-grooming behaviour with MP25, and a decrease with  $AlCl_3$  compared to control. Compared to  $AlCl_3$ , self-grooming increased with  $AlCl_3/MP25$  and  $AlCl_3/MP50$  respectively.

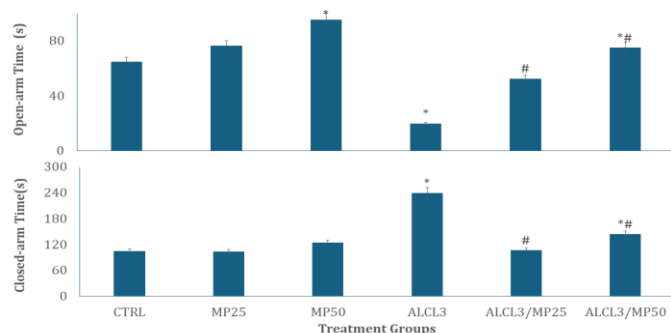


**Figure 5:** Effect of Muira puama extract on self-grooming behaviour. Each bar represents Mean  $\pm$  S.E.M, \* $p < 0.05$  significant difference from control. # $p < 0.05$  significance difference from  $AlCl_3$ . Number of rats per treatment group = 10.  $AlCl_3$ : Aluminium chloride.

### 3.6 Effect of Muira puama on anxiety related behaviours

Figure 6 shows the effect of Muira puama extract on anxiety related behaviours measured as time spent in the open arm (upper panel) and closed arm (lower panel). There was a significant ( $p < 0.001$ ) increase in open arm time with MP50 and  $AlCl_3/MP50$ , and a decrease with  $AlCl_3$  compared to control. Compared to  $AlCl_3$ , open arm time increased with  $AlCl_3/MP25$  and  $AlCl_3/MP50$  respectively.

There was a significant ( $p<0.001$ ) increase in closed arm time with  $AlCl_3$  and  $AlCl_3/MP50$  compared to control. Compared to  $AlCl_3$ , closed-arm time decreased with  $AlCl_3/MP25$  and  $AlCl_3/MP50$  respectively.



**Figure 6:** Effect of Muira puama extract on anxiety related behaviours measured as time spent in the open arm (upper panel) and closed arm (lower panel). Mean  $\pm$  S.E.M, \* $p<0.05$  significant difference from control. # $p<0.05$  significance difference from  $AlCl_3$ . Number of rats per treatment group = 10.  $AlCl_3$ : Aluminium chloride.

### 3.7 Effect of Muira puama on the oxidative stress markers and inflammatory cytokines

Table 1 shows the effect of Muira puama extract on total antioxidant capacity (TAC), malondialdehyde (MDA), Tumour necrosis factor (TNF)- $\alpha$ , and interleukin-10 levels. There was a significant ( $p<0.001$ ) decrease in TAC with  $AlCl_3$  compared to control. Compared to  $AlCl_3$ , there was a significant increase in TAC with  $AlCl_3/MP25$  and  $AlCl_3/MP50$  respectively. Levels of MDA increased significantly with MP50 and  $AlCl_3$  compared to control. However, compared to  $AlCl_3$ , MDA levels decreased with  $AlCl_3/MP25$  and  $AlCl_3/MP50$ .

There was also a significant increase in TNF- $\alpha$  with MP25, MP50,  $AlCl_3$  and  $AlCl_3/MP25$ , and a decrease with  $AlCl_3/MP50$  compared to control. Compared to  $AlCl_3$ , TNF- $\alpha$  levels decreased with  $AlCl_3/MP25$  and  $AlCl_3/MP50$  respectively. Interleukin-10 levels decreased significantly across all groups compared to control, while IL-10 levels increased with  $AlCl_3/MP25$  and  $AlCl_3/MP50$  respectively compared to  $AlCl_3$ .

### 3.5 Effect of Muira puama on the cerebral cortex histomorphology

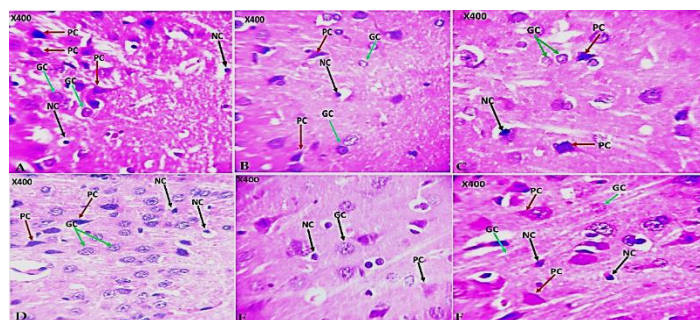
Figure 7(A - F) and 8(A - F) are representative slides of haematoxylin and eosin (H&E) and cresyl fast violet (CFV) stained sections of the rat cerebral cortex respectively. Examination of the H&E-stained slides of rats in the control group revealed distinct outer granular layer of the cerebral cortex. In the cresyl violet stained sections, the neuropil was well-delineated with multipolar shaped pyramidal cells scattered within. Also observed were granule cells with scanty cytoplasm and large open-faced nuclei (Figure 7a, 8a). In groups administered MP 25 (7B, 8B) and MP50 (7C, 8C) features similar to that observed in the control group were observed.

**Table 1: Effect of Muira puama on oxidative stress markers and proinflammatory cytokines**

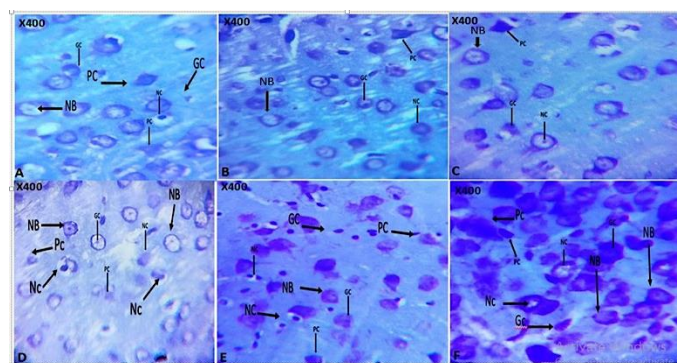
GROUPS	TAC (mM)	MDA ( $\mu$ M)	TNF-alpha (pg/ml)	IL-10 (pg/ml)
Control	14.58 $\pm$ 0.08	1.75 $\pm$ 0.02	209.53 $\pm$ 1.50	51.42 $\pm$ 14.59
MP25	15.34 $\pm$ 1.13	4.11 $\pm$ 1.31	255.95 $\pm$ 1.80*	44.96 $\pm$ 8.83*
MP50	15.28 $\pm$ 0.12	6.78 $\pm$ 0.34*	224.83 $\pm$ 2.27*	39.98 $\pm$ 13.68*
$AlCl_3$	6.79 $\pm$ 0.52*	20.95 $\pm$ 1.52*	420.57 $\pm$ 1.61*	3.76 $\pm$ 0.74*
$AlCl_3$ / MP25	15.71 $\pm$ 0.38#	8.38 $\pm$ 0.42*#	268.40 $\pm$ 2.03*#	38.73 $\pm$ 6.17*#
$AlCl_3$ / MP50	14.89 $\pm$ 0.07#	10.49 $\pm$ 0.71*#	111.94 $\pm$ 1.14*#	33.49 $\pm$ 2.65*#

Data represented as Mean  $\pm$  S.E.M, \* $p<0.05$  significant difference from control. # $p<0.05$  significant difference from  $AlCl_3$ . number of rats per treatment group =10.  $AlCl_3$ : Aluminium chloride.

In the aluminium chloride control (7D, 8D), degenerating pyramidal cell with pale staining nuclei granule cells and pyknotic glia cells were observed, whereas with  $\text{AlCl}_3/\text{MP25}$  (7E & 8E) and  $\text{AlCl}_3/\text{MP50}$  (7F & 8F) reversal of neuronal injury and preservation of Nissl bodies.



**Figure 7:** Representative photomicrograph of haematoxylin and Eosin-stained sections of the rat cerebral cortex. Observed were numerous granule cells (GC), pyramidal cells (PC), and neuroglia cells (NG) in rats in the control (7A), MP25 (7B) and MP50 (7C) groups. In the groups administered  $\text{AlCl}_3$  (7D) pale staining pyramidal and granule cells were observed with reversal of these changes with  $\text{AlCl}_3/\text{MP25}$  (7E) and  $\text{AlCl}_3/\text{MP50}$  (7F) respectively Mag X400.



**Figure 8:** Photomicrograph of cresyl violet stained sections of the rat cerebral cortex (X400). The photomicrographs show neurons scattered within the Nissl substance. Control (8A), MP25 (8B), MP50 (8C),  $\text{AlCl}_3$  (8D),  $\text{AlCl}_3/\text{MP25}$  (8E) and  $\text{AlCl}_3/\text{MP50}$  (8F) Magnification x400

#### 4 Discussion

This study evaluated the effects of *Muira puama* (MP) on changes in neurobehaviour, biochemistry, and histomorphological markers of brain integrity. The results revealed that MP exhibited a counteractive effect against the toxic actions of aluminium chloride. Exposure to  $\text{AlCl}_3$  markedly reduced body weight, feed intake, behavioural parameters, antioxidant capacity and anti-inflammatory markers; while it increased malondialdehyde and  $\text{TNF-}\alpha$  levels. The administration of *Muira puama* reversed the deleterious effects of  $\text{AlCl}_3$  across a number of parameters, including body weight, food intake, behavioural assessments, oxidative stress indicators like malondialdehyde (MDA), total antioxidant capacity (TAC) and inflammatory markers like  $\text{TNF}$  and  $\text{IL-10}$ . There were also improvements in the histopathological architecture of the brain tissue. In this study, exposure to  $\text{AlCl}_3$  significantly reduced body weight and feed intake corroborating reports of studies that had also associated exposure to  $\text{AlCl}_3$  with weight loss [15, 16, 17]. Aluminium chloride exposure was also associated with decreased feed intake. however, these reductions in body weight and feed intake were reversed by *Muira puama*.

Aluminium chloride has been reported severally to cause neurodegenerative changes in different regions of the brain including the hippocampus, cerebellum and prefrontal cortex [17, 18, 19]. In this study  $\text{AlCl}_3$  exposure was associated with behavioural and histomorphological evidence of neurodegeneration. Supporting these previous studies. Locomotor activity, rearing and self-grooming decreased with  $\text{AlCl}_3$  exposure, suggesting a central inhibitory effect. Spatial working memory also decreased while anxiety related behaviours increased significantly. The central inhibitory response to, and memory deficits observed with  $\text{AlCl}_3$  exposure have been attributed to alterations in neurotransmitters such as dopamine, serotonin and acetylcholine [16, 20]. Studies have demonstrated that cholinergic dysfunction exacerbates the loss of motor activity and self-grooming behaviours, while loss of dopaminergic transmission in the nigrostriatal pathway has been suggested to contribute to deficiencies in motor control and



exploration [16, 20]. Alterations in behaviour have also been attributed to increased inflammation and oxidative stress which was also observed in this study. Aluminium chloride toxicity has been associated with the disruption of regular neurotransmitter signalling [20, 21]. In this study, we also observed that these behavioural deficits were considerably reversed with Muira puama. Several studies have reported the ability of MP to ameliorate central nervous system disorders like anxiety, memory loss, depression and neuronal injury [22, 23, 24]. These effects have been linked to its ability to inhibit acetylcholinesterase, enhance antioxidant capacity, and modulate neurotransmitters [22, 23, 24]. The antioxidant properties of Muira puama which were also observed in this study have been previously reported. Reduced oxidative stress has also been shown to protect the dopaminergic and cholinergic systems that are essential for motor and exploratory activity [25]. Anxiety response was also reversed by muira puama administration in this study. Muira puama has been reported to modulate serotonin and gamma aminobutyric acid, neurotransmitters which have been implicated in anxiety response [26, 27].

AlCl<sub>3</sub> treatment increased levels of the pro-inflammatory cytokines (TNF) in the brain, while Muira puama modulated this increase. Current research has shown that exposure to metals like aluminium increased TNF- $\alpha$ , and the pro-inflammatory IL-10 [28]. The build-up of AlCl<sub>3</sub> causes mitochondria to release cytochrome C, which in turn raises the production of pro-inflammatory cytokines and free radicals. Moreover, it increases TNF- $\alpha$  and IL-10 gene expression [29]. Furthermore, an increase in the variability of inflammatory markers like TNF- $\alpha$  and IL-10 may be a sign of neurotoxicity brought on by AlCl<sub>3</sub> [20]. Additionally, by reducing the synthesis of inflammatory chemokines and cytokines, Muira puama has been demonstrated to reduce neuroinflammation, a characteristic in the pathophysiology of AlCl<sub>3</sub> neurotoxicity diseases like Alzheimer's Disease (AD) [30]. Muira puama is known to suppress the expression of inflammatory genes in microglia. Our findings show that Muira puama considerably reduced both inflammatory markers (TNF and IL-10) to levels comparable to those of the control group.

The neuroprotective effects of Muira puama against AlCl<sub>3</sub>-induced neurotoxicity are also supported by the result of histomorphological assessment. In the groups administered AlCl<sub>3</sub>, histological evidence of neuronal injury was observed in keeping with previous studied that had demonstrated evidence of AlCl<sub>3</sub>-induced neurodegenerative changes [15, 18, 31]. Muira puama was also observed to have reversed some of the neurodegenerative changes due to AlCl<sub>3</sub>. The neuroprotective effects of MP have been attributed to its potent antioxidant and anti-inflammatory potential as well as its ability to modulate brain neurotransmitters [24, 32].

## **Conclusion**

Muira puama administration showed significant potential in mitigating the histological and behavioural effects of aluminium chloride. Its administration was associated with improved locomotion, reduced anxiety, and preservation of the integrity of the cerebral cortex, thus targeting critical aspects of behavioural manifestations of neurodegenerative diseases. The ability to regulate oxidative stress, cytokine activity (IL-1 $\beta$  and IL-6), and antioxidant levels highlights its significant therapeutic benefits. The findings indicate the potential of Muira puama as a potential agent for managing neurodegenerative diseases and associated impairments.

## **Funding.**

None

## **Availability of data and materials**

Data generated during and analysed during the course of this study are available from the corresponding author on request.

## **Declaration of ethical approval**

Ethical approval for the research was granted by the Ethical Committee of Faculty of Basic Medical Sciences, LAUTECH with identification code (ERCFBMS/040/2024).

## **Competing interests**

All authors of this paper declare that there is no conflict of interest related to the content of this manuscript.

## **References**

1. Niu Q. Overview of the relationship between aluminium exposure and health of human being. *Adv Exp Med Biol.* 2018;1–31. doi:10.1007/978-981-13-1370-7\_1.



2. Liaquat L, Sadir S, Batool Z, Tabassum S, Shahzad S, Afzal A, Haider S. Acute aluminium chloride toxicity revisited: Study on DNA damage and histopathological, biochemical and neurochemical alterations in rat brain. *Life Sci.* 2019; 217:202–11. doi: 10.1016/j.lfs.2018.12.009.
3. Alasfar RH, Isaifan RJ. Aluminium environmental pollution: the silent killer. *Environ Sci Pollut Res Int.* 2021;28(33):44587–97. doi:10.1007/s11356-021-14700-0.
4. de Ligt R, Westerhout J, Grossouw D, Buters TP, Rissmann R, Burggraaf J, et al. Assessment of dermal absorption of aluminium from a representative antiperspirant formulation using a (26Al) Al microtracer approach: a follow-up study in humans. *Toxicol Res.* 2022;11(3):511–9. doi:10.1093/toxres/tfac029.
5. Wang L. Entry and deposit of aluminium in the brain. *Adv Exp Med Biol.* 2018; 1091:39–51. doi:10.1007/978-981-13-1370-7\_3.
6. Wong K, Riaz M, Xie Y, Zhang X, Liu Q, Chen H, et al. Review of current strategies for delivering Alzheimer's disease drugs across the blood-brain barrier. *Int J Mol Sci.* 2019;20(2):381. doi:10.3390/ijms20020381.
7. Penke B, Szűcs M, Bogár F. Oligomerization and conformational change turn monomeric  $\beta$ -amyloid and tau proteins toxic: Their role in Alzheimer's pathogenesis. *Molecules.* 2020;25(7):1659. doi:10.3390/molecules25071659.
8. Sharma K, Pradhan S, Duffy LK, Yeasmin S, Bhattarai N, Schulte MK. Role of receptors in relation to plaques and tangles in Alzheimer's disease pathology. *Int J Mol Sci.* 2021;22(23):12987. doi:10.3390/ijms222312987.
9. Zhao H, Zhou M, Liu Y, Jiang J, Wang Y. Recent advances in anxiety disorders: Focus on animal models and pathological mechanisms. *Anim Models Exp Med.* 2023;6(6):559-572.
10. Falade J, Onaolapo AY and Onaolapo OJ. Evaluation of the behavioural, antioxidative and histomorphological effects of folic acid-supplemented diet in dexamethasone-induced depression in mice. *Central Nervous System Agents in Medicinal Chemistry (Formerly Current Medicinal Chemistry - Central Nervous System Agents),* 2021;21(1), 73-8, 10.2174/1871524921666210114125355
11. Handley SL, Mithani S. Effects of  $\alpha$ 2-adrenoceptor agonists and antagonists in a maze exploration model of fear-motivated behaviour. *Naunyn Schmiedebergs Arch Pharmacol.* 1984;327(1):1-5.
12. Olofinnade AT, Onaolapo AY, Stefanucci A, Mollica A, Olowe OA, Onaolapo OJ. Cucumeropsis mannii reverses high-fat diet induced metabolic derangement and oxidative stress. *Front Biosci (Elite Ed).* 2021 Jan 1;13(1):54-76. doi: 10.2741/872.
13. Onaolapo AY, Odetunde I, Akintola AS, Ogundeji MO, Ajao A, Obelawo AY, Onaolapo OJ. Dietary composition modulates impact of food-added monosodium glutamate on behaviour, metabolic status and cerebral cortical morphology in mice. *Biomed Pharmacother.* 2019 Jan;109:417-428. doi: 10.1016/j.biopha.2018.10.172.
14. Onaolapo AY, Sulaiman H, Olofinnade AT, Onaolapo OJ. Antidepressant-like potential of silymarin and silymarin-sertraline combination in mice: Highlighting effects on behaviour, oxidative stress, and neuroinflammation. *World J Pharmacol* 2022; 11(3): 27-47. [DOI: 10.5497/wjp.v11.i3.27].
15. Promyo K, Iqbal F, Chaidee N, Chetsawang B. Aluminum chloride-induced amyloid  $\beta$  accumulation and endoplasmic reticulum stress in rat brain are averted by melatonin. *Food Chem Toxicol.* 2020 Dec;146:111829. doi: 10.1016/j.fct.2020.111829.
16. Chen X, Zhang M, Ahmed M, Surapaneni KM, Veeraraghavan VP, Arulselvam P. Neuroprotective effects of ononin against the aluminium chloride-induced Alzheimer's disease in rats. *Saudi J Biol Sci.* 2021 Aug;28(8):4232-4239. doi: 10.1016/j.sjbs.2021.06.031.
17. Agrawal M, Singhal M, Semwal BC, Arora S, Singh B, Sikarwar V, Sethi P, Chaudhary H, Akram W, Bhargava S, Kumar B, Sunam S, Kumar S. Neuroprotective action of hordenine against the Aluminium Chloride (AlCl<sub>3</sub>) induced Alzheimer's diseases & associated memory impairment in experimental rats. *Pharmacological Research - Modern Chinese Medicine.* 2024;2, 10049, doi.org/10.1016/j.prmcm.2024.100492.
18. Mohamed EA, Ahmed HI, Zaky HS, Badr AM. Sesame oil mitigates memory impairment, oxidative stress, and neurodegeneration in a rat model of Alzheimer's disease. A pivotal role of NF- $\kappa$ B/p38MAPK/BDNF/PPAR- $\gamma$  pathways. *J Ethnopharmacol.* 2021;267:113468. doi: 10.1016/j.jep.2020.113468.
19. Abdel Dayem, D., Ahmed, A., Abdel Hafez, S., Gamal El-Tahawy, N., Abdel-Aleem, S. Possible Effects of Aluminum Chloride Induced Toxicity on Hippocampus of Adult Male Albino Rats. *Minia Journal of Medical Research,* 2023; 34(3): 74-80. doi: 10.21608/mjmr.2023.215259.1408
20. Abbas F, Eladl MA, El-Sherbiny M, Abozied N, Nabil A, Mahmoud SM, Mokhtar HI, Zaitone SA, Ibrahim D. Celastrol and thymoquinone alleviate aluminum chloride-induced neurotoxicity: Behavioral psychomotor performance, neurotransmitter level, oxidative-inflammatory markers, and BDNF expression in rat brain. *Biomed Pharmacother.* 2022 ;151:113072. doi: 10.1016/j.biopha.2022.113072.
21. Adelodun ST, Ishola OA, Abijo AZ, Olatunji SY, Owolabi JO, Olanrewaju JA, Adekomi DA. Aluminium chloride-induced hippocampal damage: CA3 hippocampal subfield involvement and the neuroprotective role of Buchholzia coriacea ethanolic seed extract. *Phytomedicine Plus.* 2021;1(4),100104, doi.org/10.1016/j.phyplu.2021.100104.
22. da Silva AL, Piato AL, Ferreira JG, Martins BS, Nunes DS, Elisabetsky E. Promnesic effects of Ptychopetalum olacoides in aversive and non-aversive learning paradigms. *J Ethnopharmacol.* 2007 Feb 12;109(3):449-57. doi: 10.1016/j.jep.2006.08.022.
23. da Silva AL, Piato AL, Bardini S, Netto CA, Nunes DS, Elisabetsky E. Memory retrieval improvement by Ptychopetalum olacoides in young and aging mice. *J Ethnopharmacol.* 2004 Dec;95(2-3):199-203. doi: 10.1016/j.jep.2004.07.019.
24. Siqueira IR, Fochesatto C, Torres IL, da Silva AL, Nunes DS, Elisabetsky E, Netto CA. Antioxidant activities of Ptychopetalum olacoides ("muirapuama") in mice brain. *Phytomedicine.* 2007 Nov;14(11):763-9. doi: 10.1016/j.phymed.2006.12.007.

25. Choi HJ, Park JH, Jeong YJ, Hwang JW, Lee S, Lee H, et al. Donepezil ameliorates A $\beta$  pathology but not tau pathology in 5xFAD mice. *Mol Brain*. 2022;15(1):63.
26. Kandıř S, Altıntaş L, Kızıldağ S, Simsek F, Ateř M, Alaçam H, et al. Comparison antioxidant and neuroprotective effects of extra-virgin olive oil, donepezil and rosmarinic acid on aluminum chloride-induced Alzheimer's in rat models. *Ankara Univ Vet Fak Derg*. 2022;69(2):171–81.
27. Olofinnade AT, Ajifolawe OB, Onaolapo OJ, Onaolapo AY. Dry-feed Added Quercetin Mitigates Cyclophosphamide-induced Oxidative Stress, Inflammation and Gonadal Fibrosis in Adult Male Rats. *Antiinflamm Antiallergy Agents Med Chem*. 2024a Sep 30. doi: 10.2174/0118715230316410240821105658.
28. Al-Hazmi MA, Rawi SM, Hamza RZ. Biochemical, histological, and neurophysiological effects of long-term aluminum chloride exposure in rats. *Metab Brain Dis*. 2021;36(3):429–36.
29. Elreedy HA, Elfiky AM, Mahmoud AA, Ibrahim KS, Ghazy MA. Neuroprotective effect of quercetin through targeting key genes involved in aluminum chloride-induced Alzheimer's disease in rats. *Egypt J Basic Appl Sci*. 2023;10(1):174–84.
30. Fernandes RM, Nascimento PC, Martins MK, Aragão WAB, Rivera LFS, Bittencourt LO, et al. Evaluation of cerebellar function and integrity of adult rats after long-term exposure to aluminum at equivalent urban region consumption concentrations. *Biol Trace Elem Res*. 2021; 199:1425–36.
31. Raj K, Gupta GD, Singh S. Spermine protects aluminium chloride and iron-induced neurotoxicity in rat model of Alzheimer's disease via attenuation of tau phosphorylation, Amyloid- $\beta$  (1-42) and NF- $\kappa$ B pathway. *Inflammopharmacology*. 2021 Dec;29(6):1777-1793. doi: 10.1007/s10787-021-00883-y.
32. da Silva AL, Ferreira JG, da Silva Martins B, Oliveira S, Mai N, Nunes DS, Elisabetsky E. Serotonin receptors contribute to the promnesic effects of P. olacoides (Marapuama). *Physiol Behav*. 2008 Sep 3;95(1-2):88-92. doi: 10.1016/j.physbeh.2008.04.022